

Can Participation in Virtual Patient Simulation Improve Glaucoma Diagnosis and Management?

DISCLOSURES



SIGGI TRIER, MPharm (Germany), Medscape LLC, New York, NY, USA – none



PETER SCHOONHEIM, PHD, Medscape LLC, New York, NY, USA - none



FOTIS TOPOUZIS, MD, PHD, Aristotle University, Thessaloniki, Greece

Served as an advisor or consultant for:
Allergan, Inc.; Novartis Pharmaceuticals Corporation; Pharmaten;

Served as a speaker or a member of a speakers' bureau for:
Novartis Pharmaceuticals Corporation; Thea Pharmaceuticals;

Received grants for clinical research from:
Alcon Laboratories, Inc.; Novartis Pharmaceuticals Corporation; Pfizer Inc, Thea Pharmaceuticals

RF01-05-GLA

Purpose & Methods

PURPOSE: To determine whether virtual patient simulation can improve glaucoma diagnosis and management

METHODS:

1 Medical History

2 Patient Video Interview

3 Run Tests

4 Diagnose

5 Prescribe

6 Case Review

7 Literature Review

8 Peer Results



XFG Case: Melody F.

63 yr old F of Swedish descent, BMI 25.1, diagnosed with cataracts, glaucoma, dyslipidemia and hypertension, on latanoprost/timolol, enalapril and simvastatin, complaint: continued blurred vision, difficulties driving at night

Measure:

- Each user's pre-guidance decision = baseline
- Correct post guidance decision = improvement
- 2 tailed paired t-test for p-value

Metrics:

- >5,600 MDs outside US
- > 1,900 Ophthalmologists
- Analysis: n=336
13/04-06/06 2018

* guidance provided post decision

Programme link: <https://www.medscape.org/viewarticle/886133>



RF01-05-GLA

Results - Diagnosis

Learning Goals:

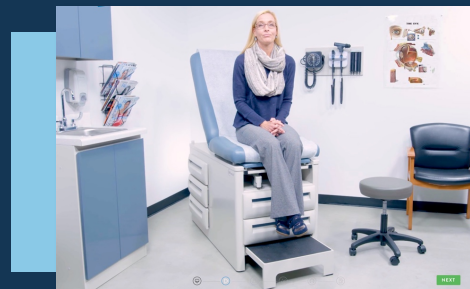- Correct diagnosis: exfoliative glaucoma (XFG)
- A decision to set an IOP target for this patient

Clues to be found:

- High remaining IOP despite dual combination therapy, IOP asymmetry, IOP fluctuation
- Exfoliative material in slit lamp exam
- Scandinavian descent, CV risk factors in medical history

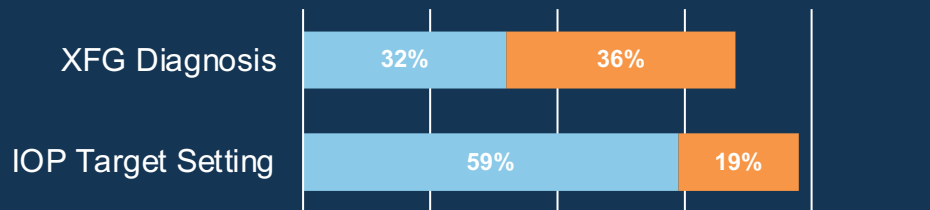
Information and choices learners were offered:

- Results: corneal pachymetry, gonioscopy, dilated fundus exam, IOP, OCT, VA, slit lamp exam, lipids, chemistry, HbA1c, BUN
- Available tests: VF, FA, IOP, MRI brain scan
- Guidance (EGS guideline/ faculty based) for each decision



VPS significantly improved competency to diagnose XFG and set an IOP target

Opht (n=336)



■ PRE CG ■ POST CG

Clinical Guidance (CG)

All behavioural changes pre-CG (%) vs post-CG (%) $P < 0.001$

RF01-05-GLA

Results - Treatment

Learning Goals:

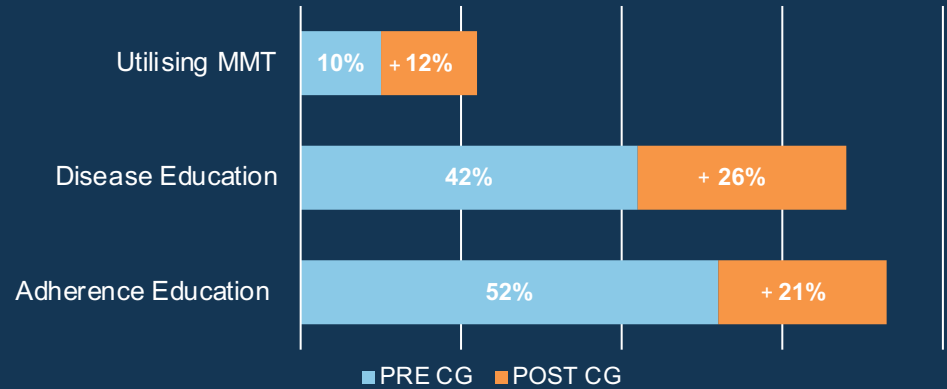
- Adding different MoA compounds to PGA/BB combination to meet target IOP
- Considering use of fixed dose combinations
- Ordering patient education on disease and adherence/ instillation technique

Information and choices learners were offered:

- Free choice from clinical database for medical therapy and surgical solutions
- Guidance (EGS guideline/ faculty based) for each decision
- Rationales for making/ not making key decisions

VPS significantly improved competency to tailor XFG treatment and adherence

Opht (n=336)



All behavioural changes pre-CG (%) vs post-CG (%) $P < 0.001$
MMT = maximum medical therapy defined as 4 agents/ 2 bottles

Rationales using latanoprost/timolol plus brimonidine/brinzolamide



RF01-05-GLA

Conclusion

Can Participation in Virtual Patient Simulation Improve Glaucoma Diagnosis and Management?

YES!

- Accredited online VPS programs that immerse and engage clinicians in an authentic and practical learning experience can improve performance and aid guideline implementation for diagnosing, treating and managing glaucoma patients and provide real world insights
- Our findings also show a continued need to educate about glaucoma subtype diagnosis, setting IOP targets and individualizing treatment regimens to improve outcomes

PATIENT CHART

Demographics | **Vitals** | **Diagnoses** | **Orders**

MELODY F.
I see you 2 weeks ago for blurry vision, and you noticed no or some eye drops for a different condition, what are the next steps?

Age: 63 years Gender: Female
Height: 1640 mm Weight: 80.3 kg
BMI: 29.5 Allergies: None

CASE DESCRIPTION

Melody is a 63-year-old woman who was referred by her primary care provider (PCP) 2 weeks ago. She was diagnosed with glaucoma and was started on laser therapy. She returns today for further evaluation.

PAST VISITS

DATE	IOP	HR	RR
Today	20	80/60	25/1
May 10, 2009	20	80/60	25/1

INTRODUCTION

HISTORY OF PRESENT ILLNESS

Melody is a 63-year-old woman who was referred to this ophthalmology clinic by her PCP after complaining of increased blurring of her vision over the past year. She clearly wears glasses, and she last had her PCP eye exam one month ago. Her prescription had changed because she could not see well at night without her glasses. She especially noted difficulty with nighttime driving due to increased glare from oncoming headlights.

Melody's initial visit to this ophthalmology clinic was 2 weeks ago. She denied any pain, redness, eye irritation, discharge, or other new symptoms other than its stated course. Her exam and evaluation were notable for glaucoma as well as elevated intraocular pressure (IOP) (see visit note for further details). She was initiated on latanoprost and laser trabeculectomy eye drops.

Today, Melody returns as scheduled with persistent, stable visual blurring but with no new complaints. She is tolerating therapy adequately without any troublesome adverse effects.

Past medical history: 5-year history of hypertension and 5-year history of hyperlipidemia

Surgical history: appendectomy at age 30

Current medications: simvastatin 40 mg once daily, enalapril 10 mg once daily, latanoprost drop 1 drop in each eye once daily

Review of systems: Negative except as above

FAMILY AND SOCIAL HISTORY

Melody is of Swedish descent. Both of her parents had hypertension and one now deceased (father following a myocardial infarction and her mother from pancreatic cancer).

Melody is married and has 3 healthy children and a healthy grandchild. She has never smoked or used illicit substances. She drinks alcohol occasionally (2 to 3 times a week).

PHYSICAL EXAMINATION NOTES

NEXT